МОРФОЛОГИЯ

УДК 616-091

T.H. GHEVONDYAN[1], I.V. ANTONYAN[1], A.V. KISHMIRYAN[1], A.A. AGABABOVA[2]

PATHOMORPHOLOGY OF THE LIVER IN CASE OF ENVENOMATION WITH VENOM OF CAUCASIAN GYURZA. EXPERIMENTAL STUDY

[1]Orbeli Institute of Physiology NAS RA, Yerevan, Republic of Armenia
[2]Buniatyan Institute of Biochemistry NAS RA, Yerevan, Republic of Armenia

A histopathological study of the liver of nonlinear mice was carried out after intraperitoneal injection of the venom of Armenian Gyurza (Macrovipera lebetina obtusa). Liver injury is observed in animals with envenomation with a dose of 2LD50. The damage reaches to maximum in animals with 4LD50 dose envenomation. Under the influence of the venom, the lobular and plate structure of the liver is disturbed, the interplate gaps compressing the walls of the sinuses expand, and balloon dystrophy develops in the cytoplasm of hepatocytes. There is an increase in the size of the nuclei of hepatocytes with an increasing disintegration of the nucleoplasm and accumulation of coarse lumps of heterochromatin along the inner surface of the nuclear membrane. The process ends with karyolysis and colliquation necrosis of the liver parenchyma. Areas of necrosis at first have a focal character, then they merge into vast areas. Intracytoplasmic glycogen is deposited in the form of crescents on the inner surface of the cell membrane of hepatocytes. The results indicate the need to assess the condition of the liver in snakebite envenomation from Gyurza and to consider the appropriateness of hepatoprotective use.

Key words: Gyurza's venom, mouse envenomation, liver histology.

Introduction. Every year 1.8-2.7 million people around the world are bitten by venomous snakes [4, 17]. Of the 22 species of snakes inhabiting the territory of Armenia, 4 species are venomous [15]. Among them, the most dangerous is the bite of the Gyurza (Macrovipera lebetina obtusa - MLO), which is often lethal. Gyurza venom belongs to the so-called hematotropic poisons. It disorders the hemostasis. The condition of the liver plays a key role in snakebite, because under normal conditions most of the factors of the haemostasis are synthesized in liver. Most of the studies of snake venom influence on the victim's body are devoted to the study of local changes at the bite site and the state of thrombosis and hemolysis in an affected person or animal. At the same time, the changes in the internal organs, occurring in envenomation mostly remained out of precise attention. The condition of internal organs begins to play a significant role in the development of the clinical course, its outcome, especially in cases of venom massive doses [3]. Therefore, a detailed study of the condition of internal parenchymal organs in the case of a snakebite acquires importance.

Aim or why is the liver chosen? The effectiveness of antivenoms and therapeutic measures against snakebites and the effectiveness of snake venoms use in the clinic should be based: a) on depth knowledge of both the composition and properties of venoms, b) on the deeper understanding of the influence of the venom on the victim's body at different structural levels of organization. In this study from preliminary examination of all histological preparations it became obvious that the most severe damage occurs in the liver. From this reason, the morphological study of the liver under the influence of single high doses of MLO venom became the aim of this study.

What means Macrovipera lebetina obtusa (MLO) and why she is called Gyurza? Macrovipera lebetina obtusa (Large east blunt-nosed viper) belongs to snake family Vipers, to genus Macrovipera [1, 5]. Macrovipera represents a genus of terrestrial and oviparous venomous vipers that inhabits Syria, the Arabian Peninsula, Iran, Iraq, Turkey, Afghanistan, West Pakistan and Northwest India. Within the former USSR, the snake is found in Armenia, Azerbaijan, in Central Asia, in Dagestan [5, 9, 12].

In Latin, Gyurza is called Vipera lebetina, which means "east viper." This eastern snake was called Gyurza because of her tight massive muscular body and large head, which resembles an old fight weapon with a thickened end - «club», in Russian «булава», which is called «gurz» in Armenian and in Persian (Figure 1).

Fig.1. On right: general view of Macrovipera lebetina obtusa. On the left: pictures from Armenian epic «David of Sasun» and from Persian epic «Shahnameh»

How to recognize the Gyurza snake? Her characteristic features. Gyurza is one of the most dangerous snakes for pets and humans. In a critical situation, she is capable of throwing body length towards the enemy, the throw time is on average 0.08 seconds (faster than a cobra), while the human reaction time is 0.1-0.2 seconds, so people are practically unable to react to throw this snake. She almost does not warn about her intention to attack, therefore even experienced snake-catchers became her victims. The powerful and stout muscular body of a large specimen is not so easy to hold in the hand. Gyurza, trying to free his head, makes sharp and strong jerks. Sometimes she even manages to bite the catcher, piercing her lower jaw for this. Gyurza is the largest representative of the viper family of snakes in the fauna of the former USSR. The length of the body together with the tail can reach almost 2 m, weight up to 3 kg. The head is very large and wide, with a sharp neck interception, the muzzle is round, the pupil and eyes are vertical. From above, the head is covered with ribbed scales, and only scales at the end of the muzzle without ribs. The supraorbital shields are absent. Above it is painted in grayish-brown tones, the pattern varies within the range. There are monochromatic individuals, almost black or brown, sometimes with a purple tint. A number of transverse dark brown spots run along the back, and smaller spots on the sides of the body. The belly is light, with small dark spots. The head is solid or with a complex pattern in the form of arcs and spots (Figure 1).

The Composition and Peculiarities of MLO Venom. The venom of MLO, a WHO category 2 species (11,15) is highly potent. When bitten, Gyurza injects 45-50 mg (dry) of poison. A mean dry venom amount of 48 mg per snake and intravenous LD50 of 12-18g/18 g mouse body weight have been reported [7,8]. The key toxic influences of M. l. obtusa venom are lethality, defibrinogenetic, hemorrhagic, phospholipase A2 activity, proteolytic, and coagulant effects. The venom of M.l. obtusa contains complex mixtures of proteins, which target the hemostatic system, preventing blood coagulation/platelet aggregation (disintegrin, C-type lectin-like proteins; L-amino acid oxidase -LAO), degrading fibrinogen (serine proteinases), disrupting the extracellular matrix of the vascular subendothelium (Zn2+- metalloproteinases), increasing the permeability of blood capillaries (VEGF) and promoting hypotension (natriuretic peptides), and exerting haemolytic and myotoxic effects (PLA2). The complex protein composition of the venom of M.l. obtusa may relate to her adaptation to rocky mountain ecosystems in order to act quickly. Particularly, the venom from M.l. obtusa contains large amounts of bradykinin-potentiating peptides (BPPs), C-type natriuretic peptides (C-NAP), proteins from dimeric disintegrin, disintegrin/ cysteine-rich fragment (DC-fragment), cysteine-rich secretory protein (CRISP), the short disintegrin obtustostatin [10,12-14).

Material and Methods. The study was carried out on nonlinear gray mice weighing 20-25 grams divided into three groups: a) healthy; b) mice, which were injected intraperitoneally with freshly diluted MLO venom at a two Median Lethal Dose - 2LD50 (2x 18,4 µg); and, c) at a dose of 4LD50 (4x 18,4 µg). Animals were killed 60 minutes after venom injection, in compliance with ethical standards. Pieces of vital organs: from liver, heart, kidneys, and brain were cut and embedded in paraffin and epoxy resins. Paraffin

sections were stained with hematoxylin-eosin, according to Van Gieson, by Mac-Manus (PAS) on glycogen. Morphometrical measurement of hepatocytic nuclei with computer program «Image J» was done. The methods of variation statistic were used to process the area and perimeter data of hepatocyte nuclei. The high dose venom testing allowed us, from one hand, to limit ourselves to a significantly small number of animals. From other hand, high doses of the venom ensure an unambiguous picture of the lesion, where we could trace the dynamics and depth of the lesion at different levels of the organ structural organization.

Results. When looking at the histological preparations, it became obvious that all the above mentioned organs were affected, and that the most profound structural abnormalities took place in the liver. Therefore, illumination and analysis of the dynamics of liver damage became the purpose of this study. The assessment of the depth of the liver lesion was made through comparison with the microscopic picture of healthy mice liver.

Microscopic Characterization of the Liver of Healthy Mice as a Control. The mouse liver has a moderately pronounced lobular structure. The contours of the sections of the lobules are mostly hexagonal or polyhedral. At the borders of the lobules, there is no perilobular connective tissue septum, characteristic for pig's liver. The lobule of the liver is preserved and clearly visible. The connective tissue structures of the liver are unremarkable, only around the portal triads and large veins are colored pink. The hepatic plates are quite clearly visible (Figure 2).

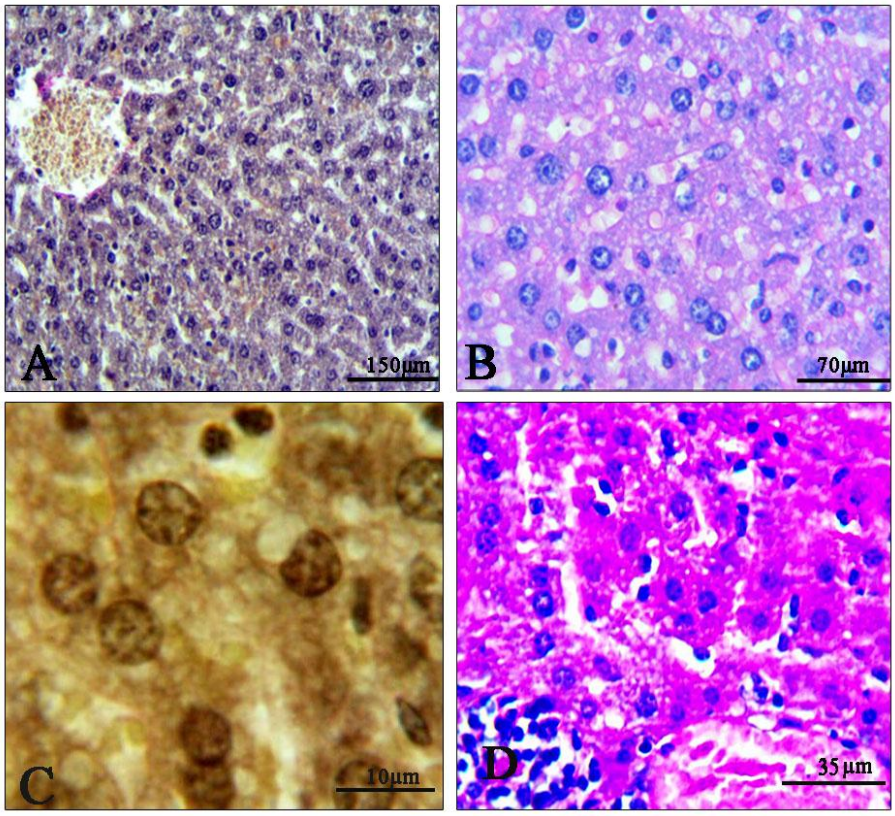

Fig. 2. The Liver Histology of Control (Healthy) Mice. Glycogen Distribution Pattern in the Liver of Control (Healthy) Mice

The plates of hepatocytes have clear contours. The capillaries in the interplate space are moderately expanded. It is possible to distinguish the transverse boundaries of the capillaries. The cytoplasm of hepatocytes contains moderate number of small and medium size vacuoles. The nuclei of hepatocytes vary in sizes; they are mostly of medium size. There are some binucleated hepatocytes. In the nuclei, there is a relatively uniform distribution of chromatin in the form of small accumulations of chromatin – heterochromatin, and in the form of moderately colored euchromatin.

Glycogen in the liver cells is unevenly distributed. Only in few hepatocytes is possible to detect a noticeable presence of glycogen. These hepatocytes are distinguished by their darker, uniform purple coloration. At low and medium magnifications of the light microscope, it is not possible to detect any graininess, which apparently indicates that glycogen is in a protein-bound state, in the form of glycoproteins. In general, a healthy mouse has a picture of a normal liver, which in mice differs to a certain extent from both the human liver and the liver of rats, and to a large extent from the liver of pigs.

The Liver Histology of Mice with Envenomation in Dose 2LD50. There is a certain loss of the lobular structure pattern of the liver. The lobular structure is moderately preserved, but the boundaries of the lobules are less distinct. There is an increase in vacuolization of the cytoplasm of hepatocytes, an increase in the size of cytoplasmic vacuoles. The narrowing of the lumen of the capillaries between the hepatic trabeculae-plates is noticeable. The trabeculae are thickened in size with some abrasion of the contours. On the background of some blurring boundaries between hepatocytes, there is an enlargement of nuclei. The inner of nuclei is clarified, the contrast between the chromatin accumulations - condensed heterochromatin and the clarified regions of the nucleoplasm - is enhanced (Figure 3).

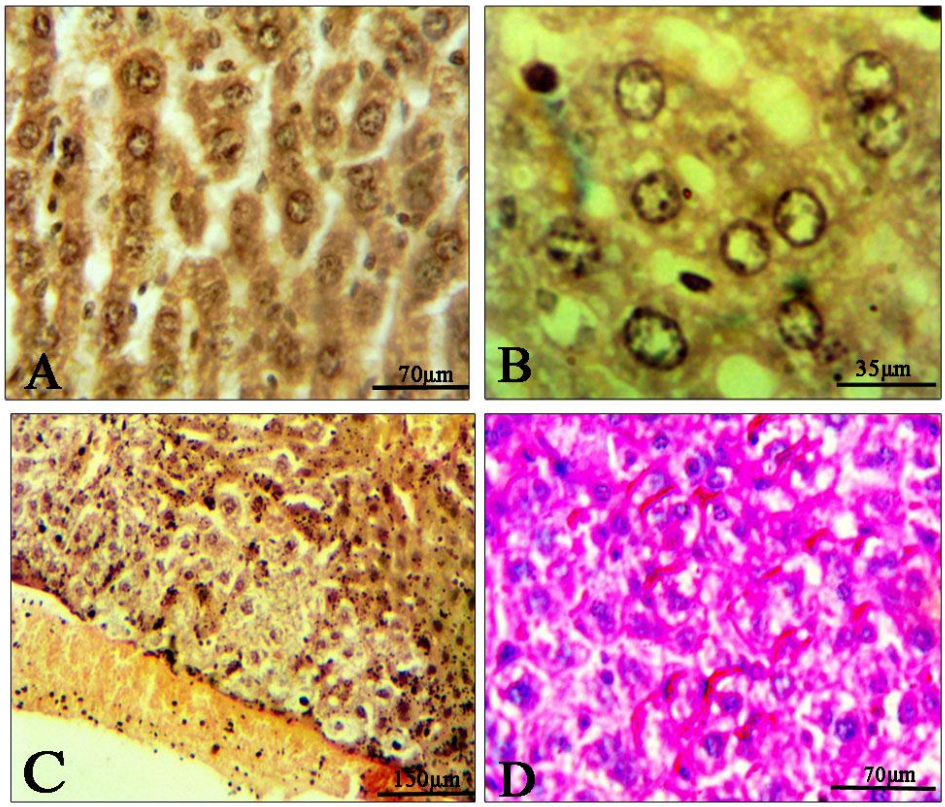

Fig. 3. Microscopic pattern of mice liver under envenomation with doses 2LD50. Intracytoplasmic glycogen distribution pattern in hepatocytes of mice with envenomation in Dose 2LD50

In preparations stained with PAS reaction, hepatocytes appear in some areas of liver parenchyma, where on the background of edema, cytoplasm clearing, large grains of glycogen are accumulated on one edge of the cell, near the cell membrane, resembling demilunes. The presence of a moderate number of small sizes necrotic foci in the parenchyma is noted. These foci of necrosis are often subcapsularly located. In general, the picture corresponds to moderate - severe liver damage, both in the form of damage of nuclei and damage of cytoplasm. The advancing changes in the liver in animals of the 2LD50 group reached their climax in the animals of the 4LD50 group.

The Liver Histology of Mice with Envenomation in Dose 4LD50. In animals of the 4LD50 group, there is a complete loss of the picture of the lobular and plate structure of the liver. The picture of strong vacuolisation - balloon dystrophy prevalence in the cytoplasm of hepatocytes. There are no clear boundaries of the cytoplasm of cells. Even the lumen and contours of the capillaries are not discernible. They are compressed by swollen, sharply enlarged hepatocytes. There are many large foci of colliquation necrosis in the liver. Some nuclei are greatly enlarged, along with a picture of kariopiknosis, karyorrhexis and karyolysis. There is a pronounced clearing of chromatin on the one hand and lumpy condensation of heterochromatin on the other. In the slides stained by PAS reaction, the number of hepatocytes with semilunar form accumulations of glycogen grains near the cell membrane is significantly increased (Figure 4). The capillaries are not detected at all, even the contours of the capillaries are not distinguishable. All capillaries are compressed by swollen and sharply enlarged hepatocytes. In the liver, there are many large foci of colliquation necrosis of rather large sizes, without signs of the presence of intact nuclei or their fragments.

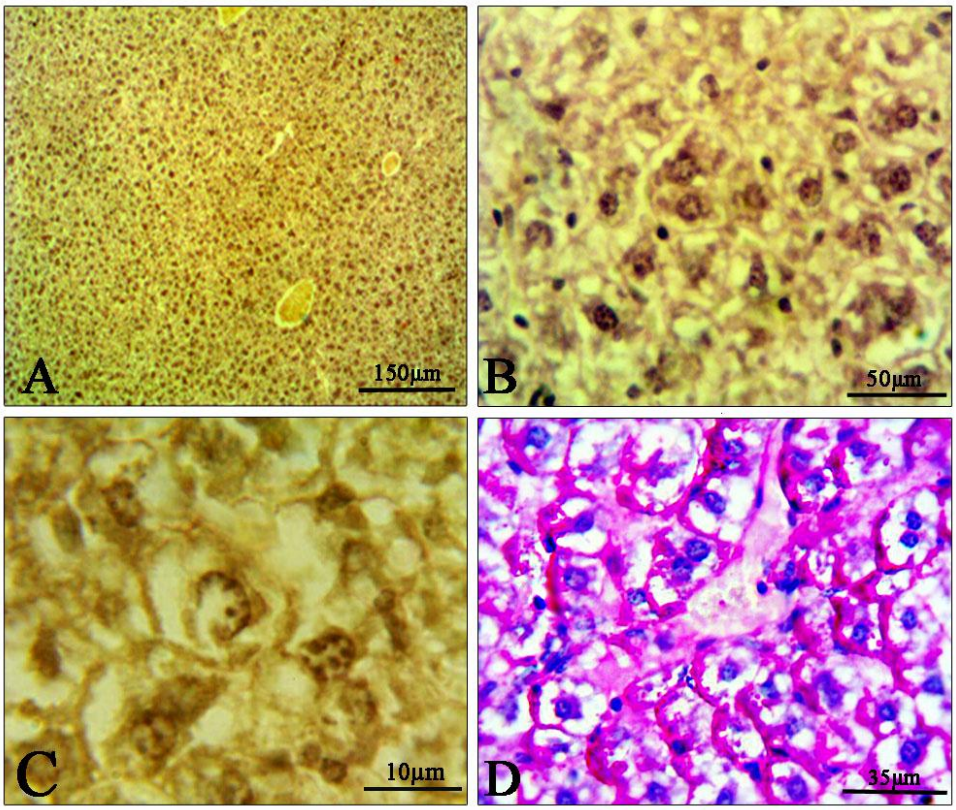

Fig. 4. Microscopic pattern of mice liver under envenomation with doses 4LD50. Intracytoplasmatic glycogen distribution pattern in hepatocytes of mice with envenomation in Dose 4LD50

In the preparations stained by the PAS reaction, the number of hepatocytes with "crescents" of glycogen grains accumulations near the cell membrane is significantly increased. Here, as in animals of the 2LD50 group, crescents have a certain one-sided orientation in all cells. In general, the picture corresponds to the most severe liver damage by the type of total damage with extensive necrosis of the liver parenchyma, which is incompatible with life. Recall that the mouse was hammered during its lifetime.

The morphometric parameters of both hepatic lobules and hepatocytes and their nuclei undergo certain changes under the influence of Gyurza venom. For example: the area of the hepatocytes nuclei increase by more than 37%, and, the perimeter of hepatocytes nuclei increases by 22% (Figure 5). The preliminary estimation of parameters of other structures and other features shows, that they can serve as indicators of liver functional condition and liver compensatory reserve.

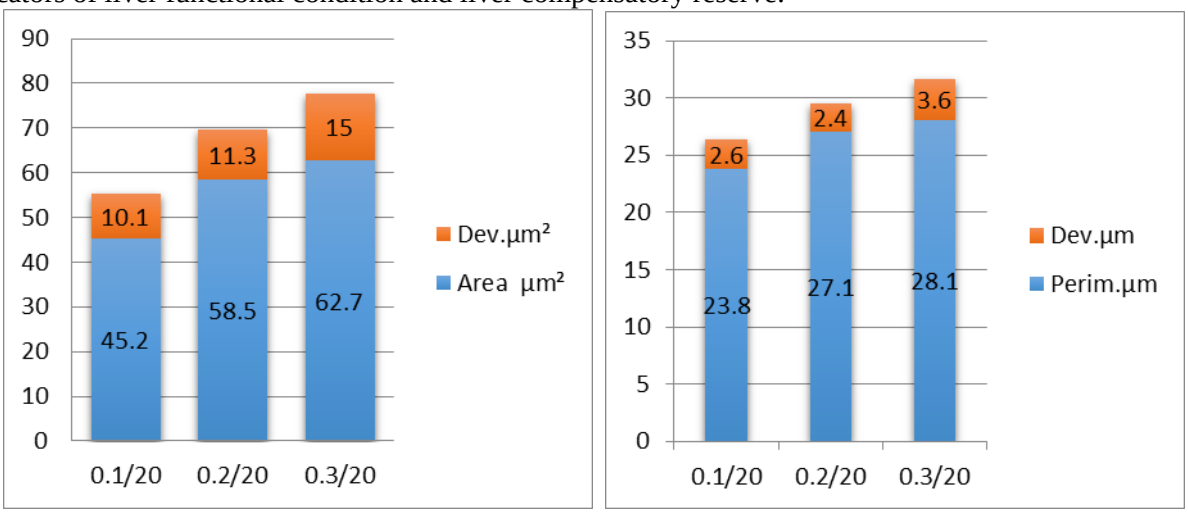

Fig. 5. Dynamics of area (left graphics) and perimeter (right graphics) changes of the hepatocytes nuclei

Discussion. The damage of cytoplasmic structures of hepatocytes caused by venom proteases are developed most rapidly, in less than 50-60 minutes. Swelling and colliquation necrosis of the cytoplasm lead

to an increase in the size of hepatocytes. They squeeze the sinusoids, the endothelium of which was the first to experience the attack of venom. Then the nucleoplasm coagulates and the genetic apparatus of the cell turns into detritus. Cell and nuclear membranes withstand the attack of venom phospholipases for a relatively long time. The nuclei of Kupffer's cells are somewhat more stable. The picture of "half moon" from the grains of glycogen is due to the cleavage of intracytoplasmic glycoprotein complexes. The withstand of glycogen may be explained by probable absent low content of amylase enzymes in venom.

At least the following structures and phenomena in the liver may become the object of morphometric measurements: changes in the nuclei, cytoplasmic vacuoles, capillary sinuses, lobular and plate structure of the liver. In the future, if there is a database of these parameters for healthy liver, these data may serve as an objective basis, a criterion for assessing the degree or depth of liver damage, accurately calculating the volume of the compensatory reserve of the liver, as well as the degree of effectiveness of the used hepatoprotectors or other drugs, antivenomics or antidotes. This statement gets significance in our institute where large scale proteomic investigations are carried out in field of MLO monoclonal antivenom development and anti-neoplastic effect investigations of the MLO venom [6,13]. Assessment of the degree of liver damage, or even a summarizing assessment of the damage degree of the liver with several other organs, may become an additional method to determination of antivenom efficiency in vivo and in vitro conditions.

Conclusion. In severe liver damage, the parenchymal nature of the organ and the intraperitoneal route of venom administration, in which the liver becomes the first target, play an important role. The data obtained also indicate the existence of a direct damaging influence of snake venom on the liver parenchyma, which is aggravated by the onset of hemostasis disorders, squeezing of sinusoids. In the coming vicious circle, the liver acts as both a starting and a closing link, turning into a trigger for developing of multiorgan failure. Of course, the treatment of envenomations by snakebite is critically dependent on the availability of effective antivenoms. At the same time the likelihood of complete or partial shutdown of the liver should be taken into account in patients with severe intoxication, and, in the clinic, steps should be taken to protection and to “short-term replacement” of at least some liver functions.

Literature:

[1]. *Ананьева Н. Б., Боркин Л. Я.,Даревский И. С.,Орлов Н. Л.* Пятиязычный словарь названий животных. Амфибии и рептилии. Латинский, русский, английский, немецкий, французский. / под общей редакцией акад. В. Е. Соколова.—М.: 1988. — С. 363.

[2]. *Ayvazyan N.M, Ghazaryan N.A.* Lipid bilayer condition abnormalities following Macrovipera lebetina obtusa snake envenomation//Toxicon. 2012. Vol. 60. P. 607-613.

[3]. *Aznauryan A.V., Silva V. Amiryan S.V.* Histopathological changes induced by the venom of the snake Vippera raddei (Armenian adder)// Toxicon. 2006. Vol. 47. P. 141-143.

[4]. *Chippaux J.* Epidemiology of snakebites in Europe: a systematic review of the literature// Toxicon, 2012. Vol.59.P. 86-89.

[5] *Dwigubski I.A.* Experience of the Natural History of all animals of the Russian Empire. University of Moscow Press, 1832. 48 p.

[6]. *Ghazaryan N.A.,Ghulikyan L.A., Kishmiryan A.V.,Kirakosyan G.R.,Nazaryan O.H.,Ghevondyan T.H.,Zakaryan N.A.,Ayvazyan N.M.* Anti-tumor effect investigation of obtustatin and crude Macrovipera lebetiobtusa venom in S-180 sarcoma bearing mice//European Journal of Pharmacology. 2015, Vol. 764. P. 340-345.

[7]. *Kurtovic T., Lang-Balija M., Ayvazyan N., Halassy B.* Paraspecificity of Vipera ammadytes-specific antivenom towards Montivipera raddei and Macrovipera lebetina obtuse venoms// Toxicon, 2014.Vol. 78.P. 103-112.

[8]. *Latifi M.* Variation in yield and lethality of venoms from Iranian snakes// Toxicon, 1984.Vol. 22.P. 373-380.

[9]. *Mallow D., Ludwig D., Nilson G.* True Vipers: Natural History and Toxinology of Old World Vipers. 0-89464-877-2, Krieger Publishing Company, Malabar, Florida 2003. 359 p.

[10]. *Murzaeva S.V., Malenov A.L., Bakiev A.G.* Proteolitic activity of viper venoms// Prikl Biokhim Microbiol, In Russian. 2000. Vol. 36. 488-491.

[11]. *Oraie H., Rastegar-Pouyani, Khosravani A., Moradi N., Akbari A., Sehhatiisabet M. E., Shafiei S., Stumpel N., Joger U.* Molecular and morphological analyses have revealed a new species of blunt-nosed viper of the genus Macropvipera in Iran// Salamandra.2018. Vol. 54.P. 233-248.

[12]. *Орлов Б.Н., Вальцева И.А.* Яды змей (токсикологические, биохимические и патофизиологические аспекты). Ташкент: Медицина.1977. 252 с.

[13]. *SanzL.,AyvazyanN.,CalveteJ.J.*Snake venomics of the Armenian mountain vipers *Macrovipera lebetina obtusa*and*Vipera raddei* // Journal of Proteomics, 2008. P. 198-209.

[14]. *Siigur J., Aaspollu A., Siigur E.* Biochemistry and pharmacology of proteins and peptides purified from the venoms of the snakes Macrovipera Lebetina subspecies// Toxicon, Vol. 158. –P. 16-32.

[15]. *Danielyan F.* Snakes in Armenia. Armenian Soviet Encyclopaedia. 1986. Vol. 12. In Armenian.Yerevan.P.539-540.

[16]. *Warrel D.A.*Snake Venoms. Chapter 4. Guidelines for the Management of Snake-Bites. WHO Library Cataloguing-in-Publication data. 2010. P. 33-34.
[17]. WHO. Snakebite envenoming. 17 May 2021. https://www.who.int/news-room/fact-sheets/detail/snakebite-envenoming

Т.А. ГЕВОНДЯН[1], И.В. АНТОНЯН[1], А.В. КАШМИРЯН[1], А.А. АГАБАБОВА[2]

ПАТОМОРФОЛОГИЯ ПЕЧЕНИ ПРИ ОТРАВЛЕНИИ ЯДОМ КАВКАЗСКОЙ ГЮРЗЫ.ЭКСПЕРИМЕНТАЛЬНОЕ ИССЛЕДОВАНИЕ

[1]Институт физиологии имени Орбели НАН Республики Армения, Ереван, Республика Армения
[2]Институт биохимии имени Буниатяна НАН Республики Армения, Ереван, Республика Армения

Резюме

Проведено патогистологическое исследование печени нелинейных мышей после внутрибрюшинного введения яда Армянской Гюрзы (*Macrovipera lebetina obtusa*). Повреждение печени отмечается у животных с интоксикацией дозой 2LD50, которое доходит до максимума у животных получивших дозу яда 4LD50. Под влиянием яда нарушается дольковое и балочное строение печени, расширяются межбалочные щели, сдавливаются синусы, в цитоплазме гепатоцитов развивается баллонная дистрофия. Происходит увеличение размеров ядер гепатоцитов с нарастанием дезинтеграции нуклеоплазмы со скоплением грубых глыб гетерохроматина. Процесс завершается кариолизисом и колликвационным некрозом паренхимы печени, Участки некрозов вначале имеют очаговый характер, затем они сливаются. Внутрицитоплазматический гликоген оседает в форме полулуний на внутренней поверхности клеточной мембраны гепатоцитов. Результаты исследования указывают на необходимость оценки состояния печени у пораженного укусом гюрзы и на рассмотрение целесообразности применения гепатопротективных средств.

Ключевые слова: яд Гюрзы, интоксикация мышей, гистология печени.